



# The saddle connective tissue graft: a periodontal plastic surgery technique to obtain soft tissue coronal gain on immediate implants. A case report

**David González, DMD, PhD**

Periodontology, Private Practice, Clínica OrtoPerio, Murcia, Spain

**Gustavo Cabello, DMD**

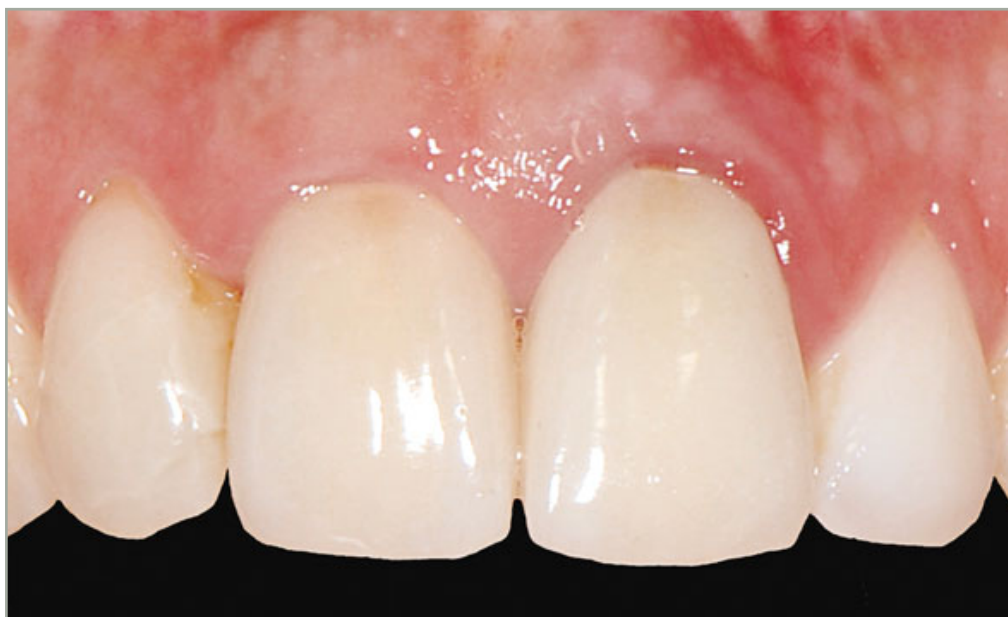Periodontology, Private Practice, Clínica Nexus, Málaga, Spain

**Gema Olmos, DMD**

Orthodontics, Private Practice, Clínica OrtoPerio, Murcia, Spain

**Carlos L. Niños, DMD**

Prosthodontist, Private Practice, Alicante, Spain



Correspondence to: David González, DMD

Clínica OrtoPerio, C.C. Centrofama, 1ª planta Avda Teniente General Gutierrez Mellado, 9 30008, Murcia, Spain;

Tel: +34 968 205434; Fax: +34 968 205433; E-mail: dr.gonzalez@ortoperio.net



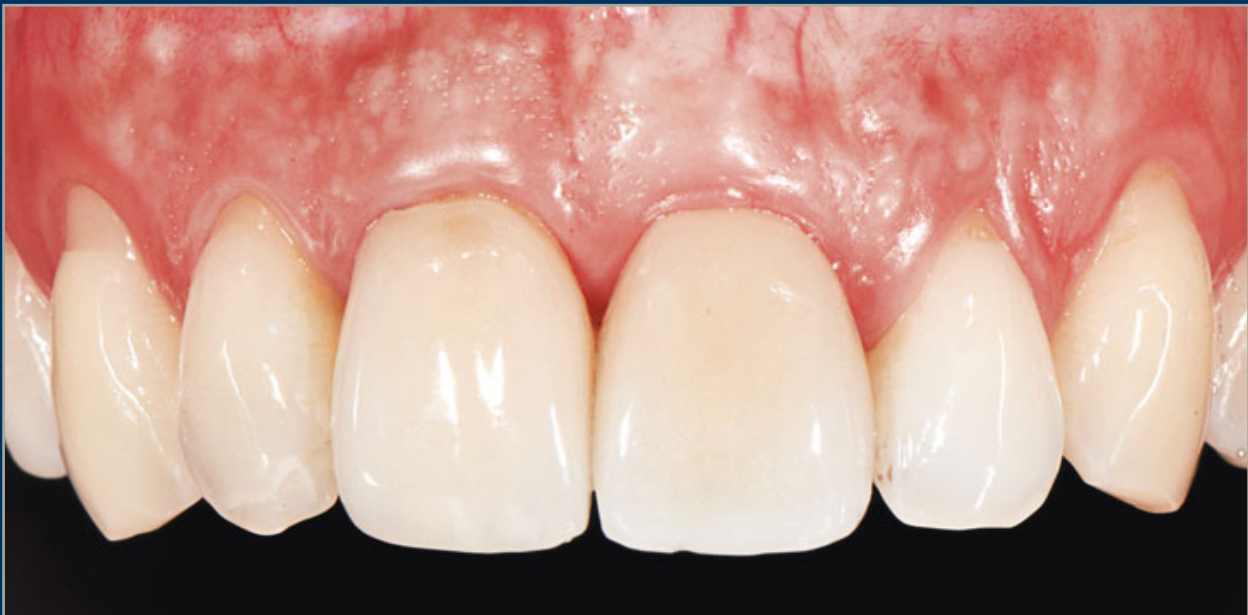copy  
all rights reserved  
Qu

## Abstract

Based on recent studies regarding the advantages of flapless immediate implants on the maintenance of the soft tissue architecture (especially at papillae level) in those situations where it is necessary to extract an anterior tooth, this case report describes a clinical procedure designed to replace a hopeless central incisor (2.1) showing root resorption adjacent to an implant-supported crown (1.1), whose gingival margin is 2 mm coronal regarding the hopeless tooth to be replaced. After the extrac-

tion of the hopeless tooth (2.1), a flapless immediate implant was placed. The implant-bone gap was then filled with bone substitute and a palatal connective tissue graft was placed *ad modum* saddle extending at buccal level from apical to the mucogingival line, sealing the socket and extending until 6 mm at palatal level *ad modum* saddle. This procedure allowed symmetry of the soft tissue margins between the two implants (1.1 and 2.1) to be obtained as well as the preservation of the inter-implant papillae (1.1).

(*Int J Esthet Dent* 2015;10:444–455)





## Introduction

Immediate implant placement is a therapy that usually achieves good health and functional results but an unpredictable esthetic result. This is because there are soft and hard tissue alterations after tooth extraction.<sup>1,2</sup>

It has been shown that a partial resorption of the buccal cortical wall occurs after tooth extraction,<sup>3</sup> resulting in a reduction in height and width of the alveolar ridge.<sup>4,5</sup> Studies in both animals and humans have shown that bone remodeling after tooth extraction is not modified by implant placement,<sup>4,5</sup> since this process is determined by resorption of the bundle bone after extraction. These findings are confirmed by clinical studies on immediate implants in humans disclosing a marginal mucosal recession > 1 mm or between 10% and 35% of the crown length.<sup>6-10</sup> However, three of those studies<sup>6,9,10</sup> were carried out with tissue-level implants placed far labially.

Other studies suggest that a flapless approach would result in a reduced alteration of the soft tissue contour, as this technique would minimize surgical trauma.<sup>11</sup> In order to reduce the recession of the peri-implant soft tissues, Araújo et al, in a study on Beagle dogs, showed a minimization of bone resorption and mucosal margin recession in immediate implants when the alveolar gap was filled with a biomaterial.<sup>12</sup>

Recent studies show that with proper three-dimensional implant positioning and bone grafting into the implant-socket, the facial gingival level can be maintained after connective tissue grafting with single, immediate tooth replacement.<sup>13-16</sup> Using this protocol, it is even

possible to achieve a slight soft tissue gain, but it might not be enough when the soft tissue margin asymmetry is 2 mm, since the temporary crown limits the facial mucosal gain.<sup>13,14</sup>

Regardless of whether stability of the facial soft tissues can be achieved, minor horizontal and vertical dimensional changes of peri-implant facial bone following immediate placement and provisionalization should be expected.<sup>17</sup>

The interproximal papillae between a tooth and an implant is related to the interproximal bone level of the tooth.<sup>18-22</sup> Therefore, the papillae will be maintained in better condition if the implant is placed without raising a flap involving the papillae.<sup>23,24</sup>

Since the papilla is a tooth-dependent structure, it is recommendable to place flapless implants immediately after extracting a tooth adjacent to an implant, as long as the alveolus is intact, in order to prevent additional soft and hard interproximal tissue loss. Besides, if the hopeless tooth already presents a gingival recession, the situation is clearly unfavorable.

In a recent study, Stimmelmayer et al<sup>25</sup> found that soft tissue stability was obtained by using a combined epithelized-subepithelial connective tissue graft simultaneous to immediate implant placement, although no data is available on coronal soft tissue gain.

## Objective

To present a technique of periodontal plastic surgery that can be useful to improving the buccal soft tissue margins in cases of immediate implants after



extracting a tooth that has a gingival margin more apical to that of an adjacent implant.

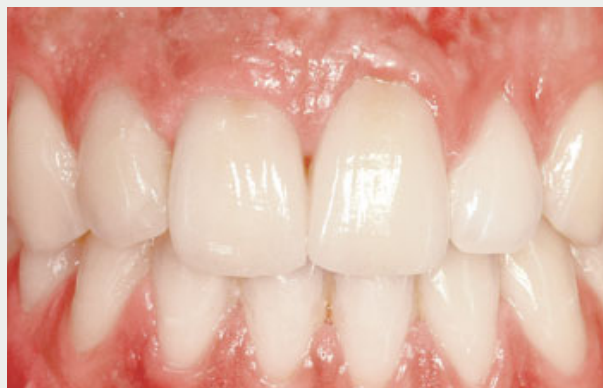## Material and methods

For the purpose of this case report, the patient was a 24-year-old woman, a non-smoker with a good health status. The patient had a Nobel Biocare Replace implant on region 1.1, which had been placed 5 years previously (Fig 1). Tooth 2.1 had its gingival margin 2 mm more apical than that of the implant on 1.1 (Fig 2) and was hopeless, since its root showed a severe external resorption at coronal third level (Fig 3).

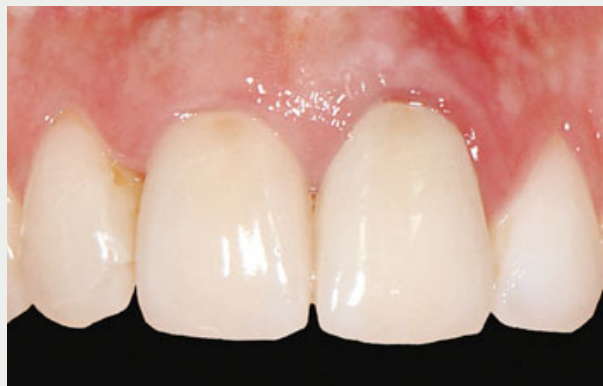The implant at 1.1 was restored with a zirconia Procera abutment and a zirconia-porcelain crown. The peri-implant tissues showed good health status without inflammatory signs, presenting a bone loss of 1.5 mm, probably due to the formation of the biologic width.

Atraumatic extraction of tooth 2.1 was carried out, maintaining the integrity of the buccal bone wall (Fig 4). Immediately after the extraction, a 4.1 mm x 12 mm Straumann Bone Level implant (Straumann) was placed without raising a flap (Fig 5). A 2 mm conic abutment was placed, after which the bone-implant gap was filled using bovine inorganic hydroxyapatite (Bio-Oss) (Fig 6). Special care was taken to place the shoulder of the implant at 2.1 position at the same level of the marginal bone loss at the adjacent implant at 1.1 position (Fig 7).

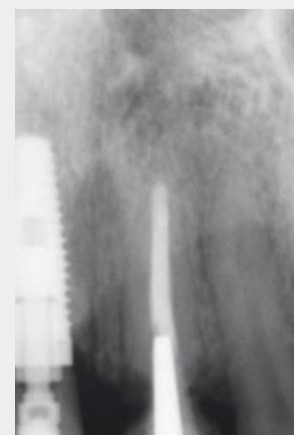A recipient zone at partial thickness *ad modum* "envelope"<sup>26</sup> was prepared by sharp dissection around the alveolus of 2.1 at buccal and palatal level using a



**Fig 1** Buccal view of the anterior zone. There is an implant at 1.1 and a hopeless tooth at 2.1. Note the asymmetry of the mucosal margins.

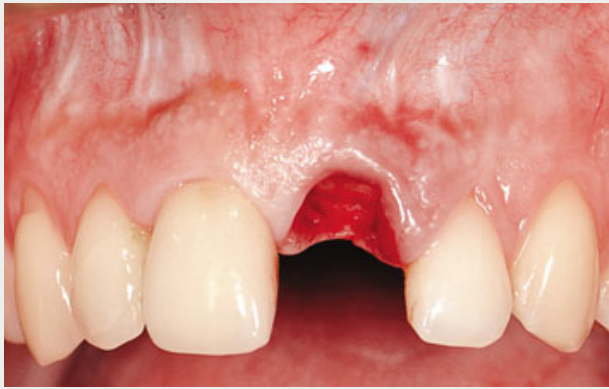

**Fig 2** A closer view of the maxillary incisors shows the more coronal position of the soft tissue margins on the hopeless tooth (left central incisor) compared to that of the implant-supported crown in the right central incisor.

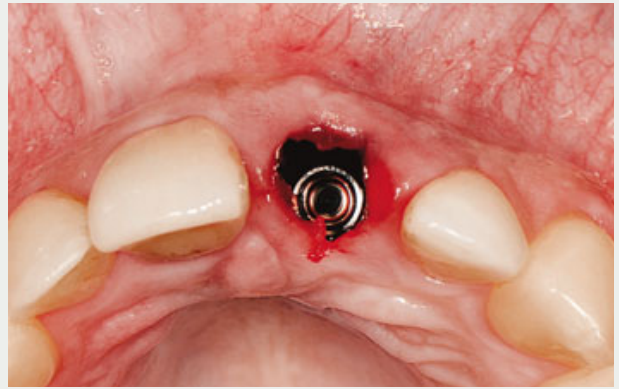


**Fig 3** Radiographic view of both central incisors. Note the 1.5 mm marginal bone loss at implant 1.1 and the severe root resorption on 2.1.

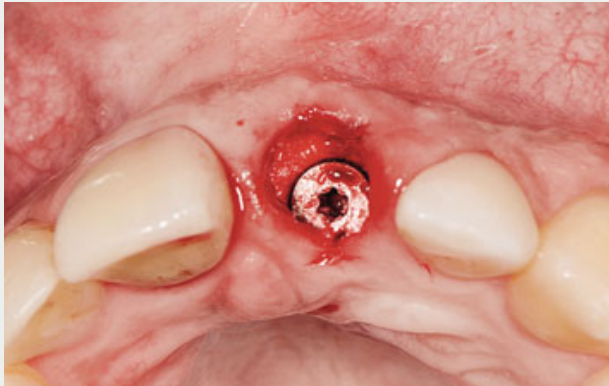




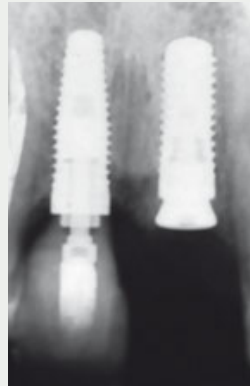
**Fig 4** Frontal view of the anterior zone after the extraction of tooth 2.1. The mucosal margin of 2.1 is already 2 mm more apical regarding that of implant 1.1.



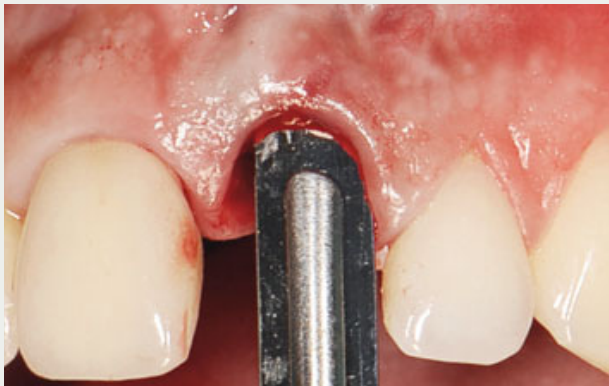**Fig 5** A 4.1 x 12 mm Straumann Bone Level implant is immediately placed at 2.1.



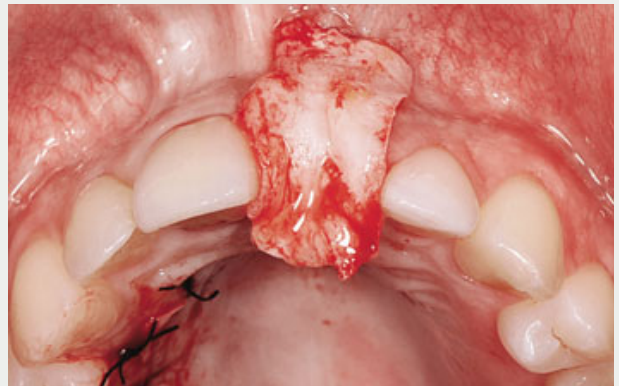
**Fig 6** After placing a 2 mm healing abutment, the implant-buccal wall gap is filled using inorganic hydroxylapatite (Bio-Oss).



**Fig 7** Radiographic view of implant at 2.1. The shoulder of the implant is at the same level regarding the marginal bone at implant 1.1.



**Fig 8** Using sharp dissection, an "envelope" recipient zone is prepared at partial thickness at buccal and palatal aspects of 2.1.



**Fig 9** A subepithelial connective tissue graft measuring 33 mm x 13 mm is obtained from the right side of the palate.



copy  
all rights reserved  
Qu

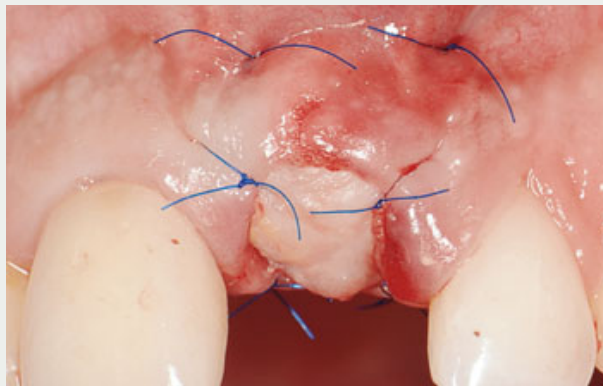
15c scalpel (Fig 8). Then, a subepithelial connective tissue graft<sup>27</sup> was obtained from the right side of the palate at pre-molar-molar level (Fig 9). It was introduced using mattress sutures to the buccal recipient zone at a more apical level regarding the mucogingival line, and then inside the palatal recipient zone in such a way that the socket remained totally covered by the graft *ad modum* saddle. Finally, the graft was fixed by four simple sutures to the free gingival margins (Figs 10 and 11). Figure 12 shows a transversal view of an immediate implant placed with soft and hard tissue graft.

## Results

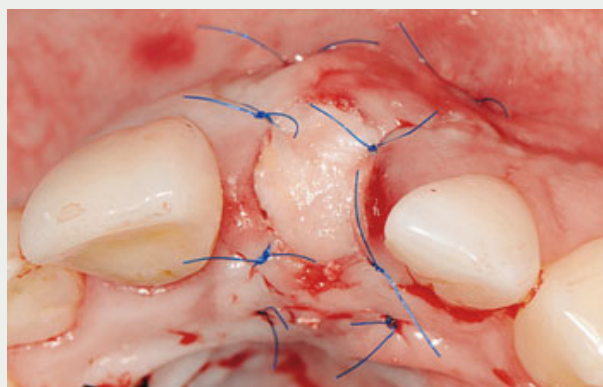
Healing was uneventful; 1 week after the implant was placed, the graft was partially integrated (Fig 13). During the 6-month healing period, the patient wore an acrylic resin Maryland bridge attached to the adjacent crowns as a temporary prosthesis (Fig 14). Six months later, the alveolar ridge in the edentulous zone showed a position far more coronal than that of the implant at 1.1 (Figs 15 and 16).

Thereafter, a second surgical phase was carried out, during which a central supracrestal incision was made without touching the interproximal margins to maintain the soft tissue gain (Fig 17). The 2 mm submerged abutment was removed and a transmucosal 6 mm abutment was placed (Fig 18).

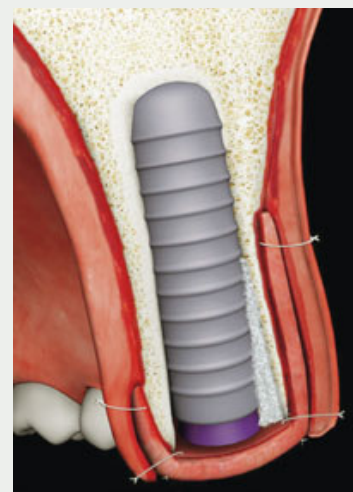
One month later, a screw-retained acrylic resin temporary crown was placed (Fig 19). This temporary crown showed an adequate emergency profile (Fig 20), keeping the soft tissue contour in harmony with those of the adjacent implant



**Fig 10** Buccal view of the graft fixed using non-resorbable 5-0 sutures.

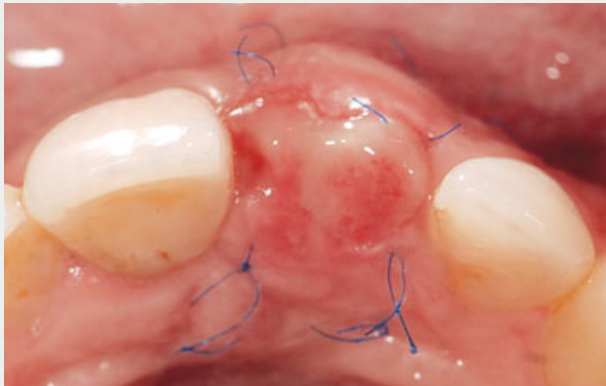


**Fig 11** Palatal view of the graft fixed by mattress and simple sutures.

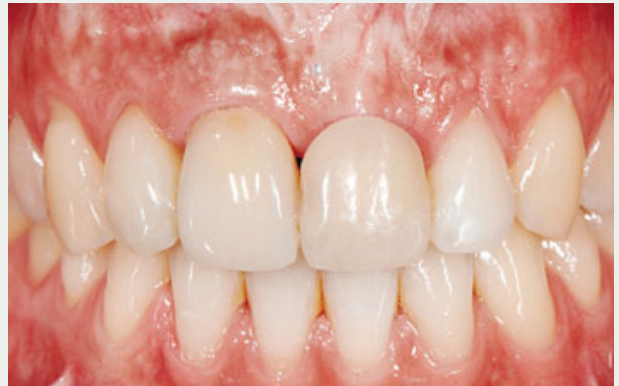

**Fig 12** Illustration of an immediate implant placed with xenograft inside the bone-implant gap and a connective tissue graft placed *ad modum* saddle from buccal through palatal view sealing the socket.

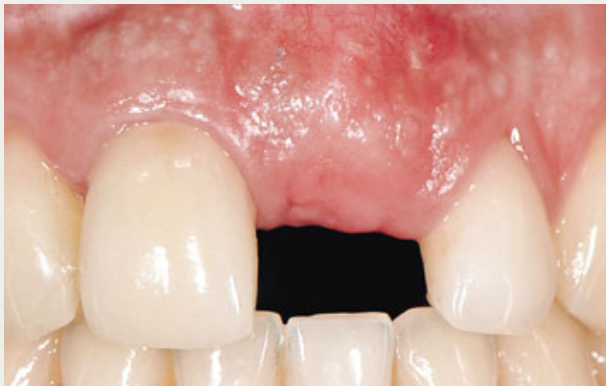



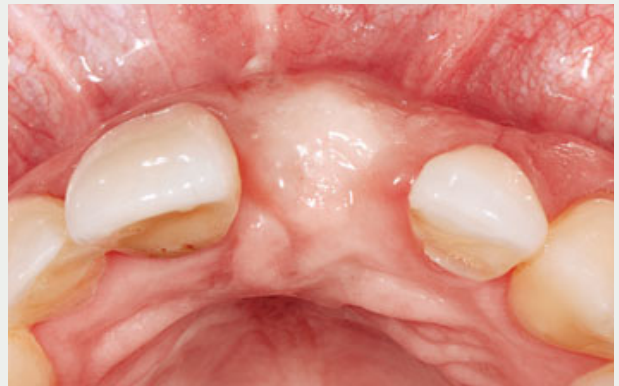**Fig 13** View of the connective tissue graft 1 week after placement. Note the integration of the graft to the surrounding tissues.



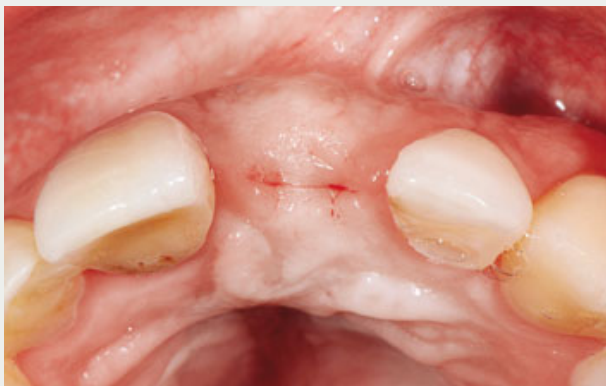**Fig 14** A Maryland bridge was placed during the 6-month healing period. The attached bridge did not have any contact with the soft tissues.



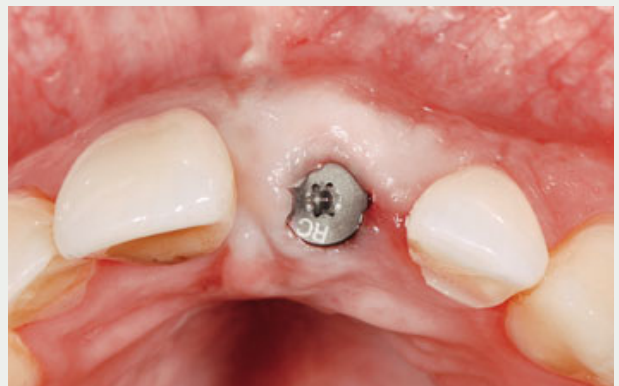**Fig 15** Buccal view at 2.1, 6 months after implant placement. Note the more coronal position of the soft tissues at the edentulous zone.



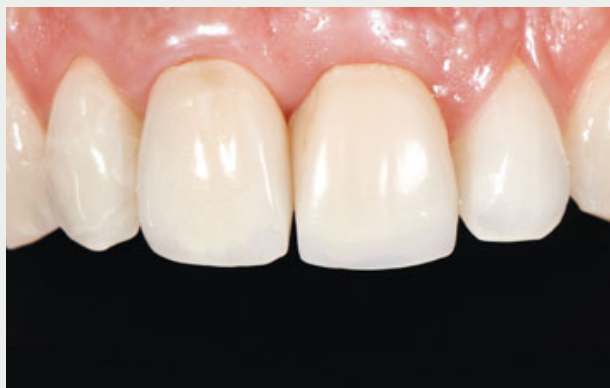**Fig 16** Occlusal view of the edentulous zone. Note the more convex aspect of the soft tissues.



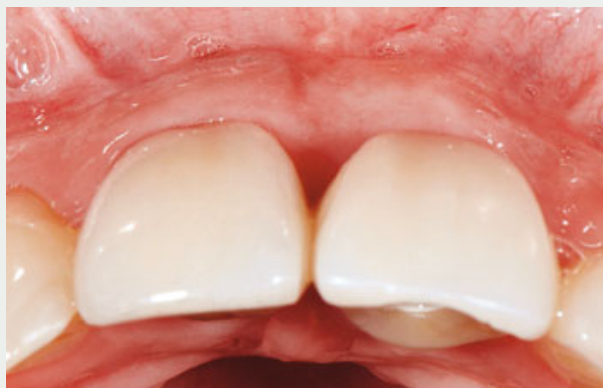**Fig 17** Supracrestal incision for second surgical phase.



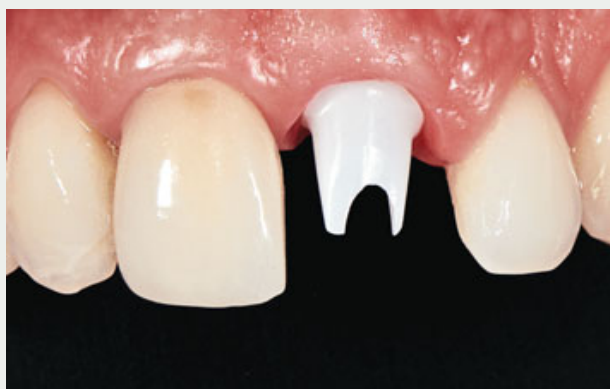**Fig 18** Occlusal view of the 6 mm-high conical healing abutment at 2.1.



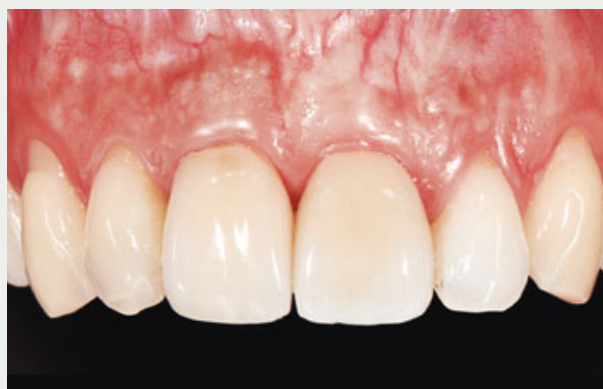**Fig 19** Acrylic resin temporary crown at the moment of delivery.



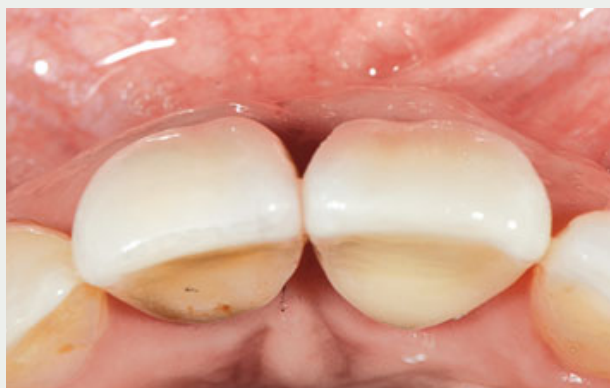**Fig 20** Occlusal view of the temporary crown, 6 months after placement. Note the buccal soft tissue volume and convexity.



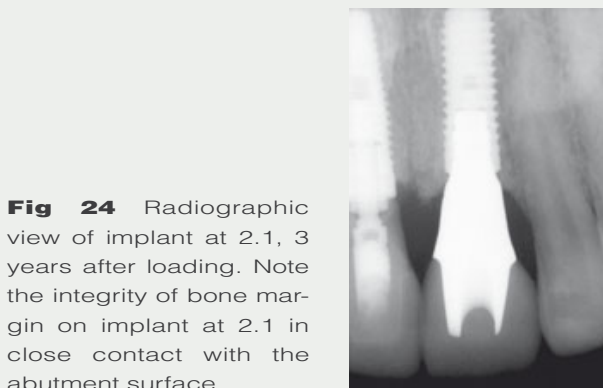**Fig 21** Zirconia abutment at 2.1.



**Fig 22** Buccal view of the anterior zone, 3 years after loading. Note the symmetry of the mucosal margins of 1.1 and 2.1.



**Fig 23** Occlusal view of the zirconia-porcelain crown, 3 years after loading. Note the adequate thickness of the soft tissue over the left central incisor.



**Fig 24** Radiographic view of implant at 2.1, 3 years after loading. Note the integrity of bone margin on implant at 2.1 in close contact with the abutment surface.





and teeth. Six months later, the final restoration, consisting of a Cares zirconia abutment (Straumann) (Fig 21) and a zirconia-porcelain crown, was placed. Three years later, the clinical assessment disclosed a healthy peri-implant status, and the soft tissue margins presented symmetry between both central incisors and a partial filling of the papilla space (Fig 22). Moreover, the mucosa at the implant on 2.1 showed an adequate horizontal volume (Fig 23). The 3-year radiographic evaluation showed complete stability of the marginal bone, even presenting a coronal bone peak between both implants (Fig 24).

## Discussion

The challenge faced in the present case was the need to extract a hopeless left central incisor with a gingival margin 2 mm more apical regarding that of the adjacent implant at 1.1. The papillae between the implant (1.1) and the hopeless tooth (2.1) presented a good aspect. However, since the papillae between an implant and a tooth depends on the interproximal bone level of the tooth, it is assumed that after tooth extraction, the loss of the bone crest would result in a partial loss of the papillae and a more apical migration of the mucosal margin at 2.1 zenith.

In this case, to avoid any alteration in the mucosal margin of the adjacent restoration (1.1), it was not recommendable to place the implant on a staged protocol, not even *ad modum* early placement,<sup>28,29</sup> since in those cases, after 6 to 8 weeks, it becomes necessary to expose the interproximal bone of

the adjacent implant at the moment of raising a flap for implant placement, resulting in increased bone resorption. A papilla-sparing incision could have been made in this zone, but this would have run a high risk of causing a scar in the facial aspect due not only to the normal healing of the incision, but also because of the tension resulting from the volume augmentation of the guided bone regeneration procedure usually needed when implants are placed on an early protocol.

To prevent such negative effects at soft tissue level, it was decided to place an immediate implant. However, another problem was that even if it were possible to maintain the current level of the soft tissues, the future restoration would have a mucosal margin 2 mm more apical than that of the adjacent implant at 1.1. Therefore, it was necessary to have an additional 2 mm facial soft tissue gain in order to obtain symmetry on both mucosal implant margins (1.1 and 2.1).

If an immediate temporary crown had been placed, it would only have maintained the current margins. It was therefore mandatory to perform one or other periodontal plastic surgery technique to gain even more soft tissue by submerging the implant. Since symmetry between both restorations was the main goal, the implant was placed at exactly the same apicocoronal level regarding the marginal bone of the adjacent implant, not at the level of the implant shoulder. This was because the kind of implant placed at 2.1 position usually preserves the marginal bone, and the implant at 1.1 position already had a 1.5 mm bone loss.

With this aim in mind, after placing the implant, filling the bone-implant gap, and placing a 2 mm abutment, a buccal



and palatal recipient zone *ad modum* “envelope”<sup>26</sup> at 2.1 level was prepared. Then, a subepithelial connective tissue graft was obtained from the right side of the palate, which was introduced and fixed inside the envelope, totally covering the socket. The nutrition coming from the buccal and palatal soft tissues produced a complete revascularization of the connective tissue graft, obtaining a vertical and horizontal increase of the soft tissues at 2.1 level.

Landsberg et al<sup>30</sup> described the socket seal using a free epithelized gingival graft to preserve the alveolus after an extraction in order to place an implant posteriorly. Later, Landsberg<sup>31</sup> described the placement of an immediate implant combined with a socket seal. The healing of this surgical approach presents a high risk of necrosis of the graft since its blood supply depends on the gingival part of the socket and the subjacent blood clot.

Stimmelmayer et al<sup>25</sup> described the use of a combined epithelized-connective tissue graft following implant placement. Although this procedure usually obtains good results, there is an increased morbidity of the donor site due to the healing by second intention. Besides, keeping the epithelium results in a more keratinized tissue that will produce a color scar or will have to be removed later.

Kan et al<sup>13</sup> reported that after immediate placement and restoration by adding a connective tissue graft on the buccal aspect, a 0.13 mm facial soft tissue gain can be obtained after 1 year. Cornellini et al<sup>14</sup> obtained a 0.2 mm facial soft tissue gain using the same protocol. Grunder<sup>16</sup> found a 0.31 mm labial volume gain using a connective tissue graft placed *ad*

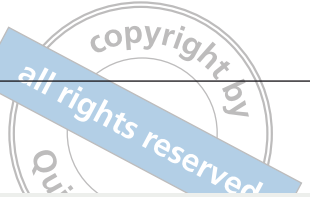
*modum* “tunnel”, whereas there was a 1.063 mm labial volume loss without a soft tissue graft.

The technique described in this case report has certain risks and should be performed by experienced and skillful operators since a perforation of the buccal or palatal tissue can occur when making the pouch. Furthermore, necrosis of the graft can also occur, which is prevented by the double vascularization from the buccal and palatal aspects that nourishes the part of the graft over the implant.

This procedure needs a second surgical site to obtain the connective tissue graft, but the approach is justified since the potential benefit is to increase the amount of soft tissue not only horizontally but also vertically. Finally, the procedure is more expensive.

The authors are of the opinion that had a temporary crown been placed, it would have inhibited the soft tissue coronal gain of 2 mm that would have been necessary to obtain symmetry with the other central incisor (implant-supported restoration). The saddle connective tissue graft totally sealed the socket, isolating the blood clot. This allowed an excess of soft tissue that finally resulted in the facial gingival tissue gain necessary to obtain symmetry and the maintenance of the papillae at the mesial and distal aspects.

Even though the expectations of the patient were fulfilled by the attainment of a proper esthetic result with an adequate emergency profile of the crown and maintenance of the inter-implant papillae, the present article has the limitations of a case report, and more research needs to be carried out to ascertain whether this is a viable approach with predictability.



## References

1. Pietrokovski J, Massler M. Alveolar ridge resorption following tooth extraction. *J Prosthet Dent* 1967;17:21–27.
2. Schropp L, Wenzel A, Kostopoulos L, Karring T. Bone healing and soft tissue contour changes following single-tooth extraction: a clinical and radiographic 12-month prospective study. *Int J Periodontics Restorative Dent* 2003;23: 313–323.
3. Araújo MG, Lindhe J. Dimensional ridge alterations following tooth extraction. An experimental study in the dog. *J Clin Periodontol* 2005;32:212–218.
4. Araújo MG, Sukekava F, Wennström JL, Lindhe J. Ridge alterations following implant placement in fresh extraction sockets: an experimental study in the dog. *J Clin Periodontol* 2005;32:645–652.
5. Botticelli D, Berglundh T, Lindhe J. Hard-tissue alterations following immediate implant placement in extraction sites. *J Clin Periodontol* 2004;31:820–828.
6. Chen ST, Darby IB, Reynolds EC. A prospective clinical study of non-submerged immediate implants: clinical outcomes and esthetic results. *Clin Oral Implants Res* 2007;18:552–562.
7. Juodzbaly G, Wang HL. Soft and hard tissue assessment of immediate implant placement: a case series. *Clin Oral Implants Res* 2007;18:237–243.
8. Kan JY, Rungcharassaeng K, Sclar A, Lozada JL. Effects of the facial osseous defect morphology on gingival dynamics after immediate tooth replacement and guided bone regeneration: 1-year results. *Int J Oral Maxillofac Surg* 2007;36(7 suppl 1):13–19.
9. Evans CD, Chen ST. Esthetic outcomes of immediate implant placements. *Clin Oral Implants Res* 2008;19:73–80.
10. Chen ST, Darby IB, Reynolds EC, Clement JG. Immediate implant placement postextraction without flap elevation. *J Periodontol* 2009;80:163–172.
11. Fickl S, Zuhr O, Wachtel H, Boltz W, Huerzeler M. Tissue alterations after tooth extraction with and without surgical trauma: a volumetric study in the beagle dog. *J Clin Periodontol* 2008;35:356–363.
12. Araújo MG, Linder E, Lindhe J. Bio-Oss collagen in the buccal gap at immediate implants: a 6-month study in the dog. *Clin Oral Implants Res* 2011;22:1–8.
13. Kan JY, Rungcharassaeng K, Morimoto T, Lozada J. Facial gingival tissue stability after connective tissue graft with single immediate tooth replacement in the esthetic zone: Consecutive case report. *J Oral Maxillofac Surg* 2009;67(11, suppl):40–48.
14. Cornellini R, Barone A, Covani U. Connective tissue grafts in postextraction implants with immediate restoration: a prospective controlled clinical study. *Prac Proced & Aesthet Dent* 2008;20:337–343.
15. Cornellini R, Cangini F, Covani U, Wilson T. Immediate restoration of implants placed into fresh extraction sockets for single tooth replacement: a prospective clinical study. *Int J Periodontics Restorative Dent* 2005;25:439–447.
16. Grunder U. Crestal ridge width changes when placing implants at the time of tooth extraction with and without soft tissue augmentation after a healing time of 6 months: report of 24 consecutive cases. *Int J Periodontics Restorative Dent* 2011;31:9–17.
17. Roe P, Kan JY, Rungcharassaeng K, Caruso JM, Zimmerman G, Mesquida J. Horizontal and vertical dimensional changes of peri-implant facial bone following immediate placement and provisionalization of maxillary anterior single implants: a 1-year cone beam computed tomography study. *Int J Oral Maxillofac Implants* 2012;27:393–400.
18. Jemt T. Regeneration of gingival papillae after single-implant treatment. *Int J Periodontics Restorative Dent* 1997;17: 326–333.
19. Choquet V, Hermans M, Adriaenssens P, Daelemans P, Tarnow DP, Malevez C. Clinical and radiographic evaluation of the papilla level adjacent to single-tooth dental implants. A retrospective study in the maxillary anterior region. *J Periodontol* 2001;72:1364–1371.
20. Kan JY, Rungcharassaeng K, Umezu K, Kois JC. Dimensions of peri-implant mucosa: an evaluation of maxillary anterior single implants in humans. *J Periodontol* 2003;74:557–562.
21. Henriksson K, Jemt T. Measurements of soft tissue volume in association with single-implant restorations: a 1-year comparative study after abutment connection surgery. *Clin Implant Dent Relat Res* 2004;6:181–189.
22. Cardaropoli G, Lekholm U, Wennström JL. Tissue alterations at implant-supported single-tooth replacements: a 1-year prospective clinical study. *Clin Oral Implants Res* 2006;17:165–171.
23. Gomez-Roman G. Influence of flap design on peri-implant interproximal crestal bone loss around single-tooth implants. *Int J Oral Maxillofac Implants* 2001;16:61–67.





24. Block MS, Mercante DE, Lirette D, Mohamed W, Ryser M, Castellon P. Prospective evaluation of immediate and delayed provisional single tooth restorations. *Intl J Oral Maxillofac Surg* 2009; 67(11, suppl):89–107.
25. Stimmelmayer M, Allen EP, Reichert TE, Iglhaut G. Use of a combination epithelized-subepithelial connective tissue graft for closure and soft tissue augmentation of an extraction site following ridge preservation or implant placement: description of a technique. *Int J Periodontics Restorative Dent* 2010;30:375–381.
26. Raetzke PB. Covering localized areas of root exposure employing the “envelope” technique. *J Periodontol* 1985;56:397–402.
27. Langer B, Langer L. Subepithelial connective tissue graft technique for root coverage. *J Periodontol* 1985;56:715–720.
28. Buser D, Hallbritter S, Hart C, et al. Early implant placement with simultaneous guided bone regeneration following single-tooth extraction in the esthetic zone: 12-month results of a prospective study with 20 consecutive patients. *J Periodontol* 2009;80:152–162.
29. Belser U, Grütter L, Vailati F, Bornstein MM, Webber HP, Buser D. Outcome evaluation of early placed anterior maxillary single-tooth implants using objective esthetic criteria: a cross-sectional, retrospective study in 45 patients with a 2- to 4-year follow-up using pink and white esthetic scores. *J Periodontol* 2009;80:140–151.
30. Landsberg CJ, Bichacho N. A modified surgical/prosthetic approach for optimal single implant supported crown. Part I – The socket seal surgery. *Pract Periodontics Aesthet Dent* 1994;6:11–17.
31. Landsberg CJ. Socket seal surgery combined with immediate implant placement: a novel approach for single-tooth replacement. *Int J Periodontics Restorative Dent* 1997;17:140–149.