

CLINICAL REPORT

Maxillary zirconia and mandibular composite resin-lithium disilicate—modified PEEK fixed implant-supported restorations for a completely edentulous patient with an atrophic maxilla and mandible: A clinical report

Gustavo Cabello-Domínguez, DMD, MS,^a Javier Pérez-López, RDT,^b Beatriz Veiga-López, RDT,^c David González, DMD, PhD,^d and Marta Revilla-León, DDS, MSD^e

Implant-supported restorations for completely edentulous patients may be more challenging than for partially edentulous patients.^{1,2} Fixed prostheses may be contraindicated because of the need for additional lip support.^{1,2} For such patients, implant-retained overdentures may be the treatment of choice.³⁻⁶

Material selection is important for complete-arch implant-supported prostheses.⁷⁻¹³ Good outcomes have been reported for metal-ceramic restorations,¹⁴ while maxillary metal-acrylic resin prostheses have been reported to have an increased incidence of esthetic, phonetic, and maintenance problems.^{1-4,9} A design addressing the rehabilitation of the dental aspects and the alveolar process and its associated soft tissues separately has been suggested.^{7,8} Bimaxillary metal-ceramic implant-supported restorations may increase the incidence of mechanical complications including fracture of the veneering ceramic or present an unpleasant clicking sound during function.

New restorative materials such as monolithic zirconia¹⁵⁻²⁰ and polyetheretherketone (PEEK)²¹⁻²⁶ have been used for implant-supported restorations with promising

ABSTRACT

Bimaxillary implant-supported restorations for edentulous patients must include a comprehensive diagnosis, treatment plan, and careful selection of the restorative materials. The present clinical report described a completely edentulous patient rehabilitated with a zirconia framework with a facial ceramic veneer on the maxillary arch and a modified polyetheretherketone (PEEK) framework with gingival composite resin and cemented lithium disilicate crowns on the mandibular arch. The rationale for this combination of restorative materials is reviewed. (J Prosthet Dent 2019;■:■-■)

success rates¹⁵⁻²⁵ and have been suggested as an alternative to metal-ceramic and metal-resin restorations.^{15-17,27-31} PEEK has a relatively low elastic modulus of about 3.5 GPa,³² good biocompatibility,^{26,33,34} good polishability,³³ low plaque affinity,³³ and high bond strength to composite resin.^{35,36}

The present clinical report describes a monolithic zirconia restoration with facial ceramic on the maxillary arch and a PEEK framework with gingival composite resin and cemented lithium disilicate crowns on the mandibular arch. The rationale for this combination of different restorative dental materials is reviewed.

CLINICAL REPORT

A 56-year-old woman visited the author's private practice seeking a "solution to the problem of my

^aPrivate practice, Málaga, Spain.

^bDirector, Laboratory Oral Design, Lugo, Spain.

^cCo-Director, Dental Laboratory Technician, Oral Design, Lugo, Spain.

^dPrivate practice, Murcia, Spain.

^eAssistant Professor and Assistant Program Director AEGD, College of Dentistry, Texas A&M University, Dallas, Texas; and Affiliate Assistant Professor Graduate Prosthodontics, University of Washington, Seattle, Wash; and Researcher, Revilla Research Center, Madrid, Spain.

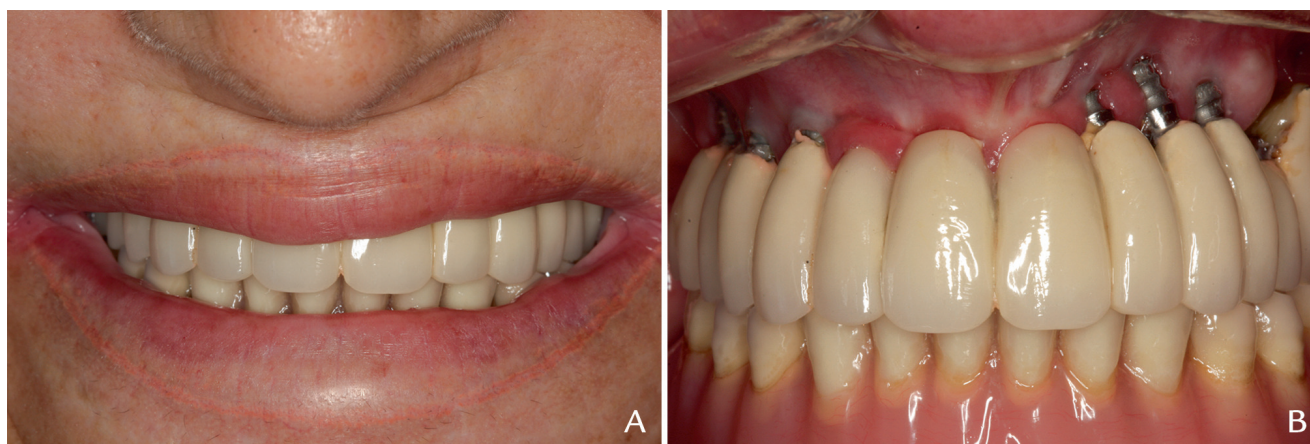


Figure 1. Pretreatment appearance. A, Smile view. B, Maximum intercuspation.

prostheses, which have resulted in signs of infection and caused me to feel insecure and even depressed.” The extraoral analysis revealed a facial midline coincident with the maxillary dental midline, but the occlusal plane was not parallel to the horizontal facial plane. The maxillary incisors were not displayed at rest, the smile line was straight, and the lip line was low (Fig. 1A). The patient had a maxillary complete-arch metal-ceramic implant-supported restoration and a mandibular implant-retained overdenture. All implants exhibited gingival recession with signs of inflammation accompanied by peri-implant pockets and bleeding on probing, symptoms consistent with active peri-implantitis (Fig. 1B). The radiographic examination revealed a bone loss of 50% to 60% around all the maxillary and mandibular dental implants (Fig. 2). The patient was offered the option of keeping her prostheses after treatment for the peri-implantitis. She opted for a retreatment that involved a new maxillary and mandibular implant-supported restoration after removal of all the affected dental implants.

Diagnostic casts were mounted on a semi-adjustable articulator (Artex CT; Amann Girrbach). A surgical guide was prepared by using the current tooth positions, and an acrylic resin template of the maxillary teeth was prepared to facilitate fabrication of the interim restorations.³⁷

The maxillary implants were removed, and 6 new implants were placed (Table 1). A complete-arch screw-retained interim restoration was fabricated by using the maxillary acrylic resin template³⁷ and maintaining the previously measured vertical dimension of occlusion (VDO).²⁸ Subsequently, the 4 mandibular implants were removed, and 4 dental implants were placed (Table 1). The mandibular overdenture was

relined and converted into a screw-retained interim restoration, maintaining the previously measured VDO (Fig. 3).

During the osseointegration of the implants, no surgical or prosthetic complications occurred.^{38–42} Before the maxillary and mandibular screw-retained interim restorations were removed, a facebow record (Artex Facebow; Amann Girrbach) and an interocclusal registration were obtained (Fig. 4). A maxillary and mandibular open-tray complete-arch implant impression procedure using rigid splinting, a custom tray, and polyether impression material (Impregum Penta Medium Body; 3M ESPE) was used.⁴³

The maxillary and mandibular interim restorations were used to mount the definitive casts on the same articulator. Silicone indices (Lab-Putty hard; Coltène) (Fig. 5) were obtained to duplicate the interim restorations⁴⁴ (Fig. 6) and as a reference for the diagnostic waxing, increasing the tooth visibility at rest, obtaining a convex smile line, an occlusal plane parallel to the bipupillary and intercommissural lines, and improving tooth anatomy. After the esthetic evaluation, maxillary and mandibular screw-retained interim restorations with a convex intaglio surface were fabricated and delivered (Fig. 7). No significant issues were encountered during a 6-month follow-up period.

The second maxillary and mandibular screw-retained interim restorations were digitized and used as a reference to design the definitive restorations. For the maxilla, a milled monolithic zirconia (Nacera Pearl Multilayer; Nacera) framework with a facial ceramic veneer (Creation Zi-CT A1 Dentine; Creation) and a gingival veneer (Creation Zi-CT Gingival; Creation) was made (Fig. 8). A milled high-resistance modified PEEK (Pekkton ivory; Cendres+Métaux) framework was fabricated for the

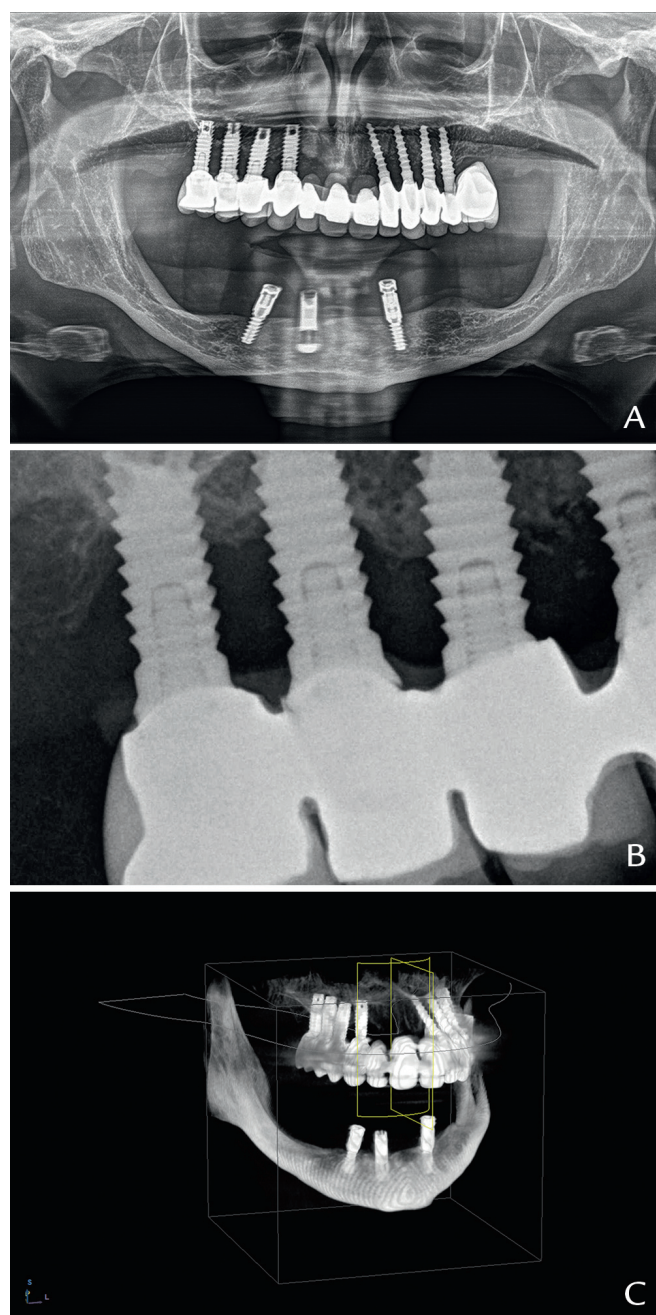


Figure 2. Pretreatment radiographs. A, Panoramic radiograph. B, Periapical radiograph of maxillary right implants. C, Cone beam computed tomograph.

mandibular prosthesis, with lithium silicate crowns (e.max Press LT A-1; Ivoclar Vivadent AG) and gingival composite resin (anaxgum Pink Composite; Anaxdent) (Fig. 9).⁷ Both frameworks were cemented on titanium abutments with a resin cement (PANAVIA SA Cement Plus; Kuraray) following the manufacturer's recommendations.

Table 1. Summary of treatment completed

Clinical Interventions Detail	Maxillary Arch	Mandibular Arch
Number of implants removed	8	3
Number of implants placed	6	4
Position of placed implants and implant description	Right and left canines (RC implant; Straumann) Right and left first premolars (RN implant; Straumann) Right and left first molars (WN implant; Straumann)	Right and left second premolar, right lateral incisor and left lateral incisor positions (RC implant; Straumann)
First interim restorations	Acrylic resin shell relined to fabricate screw-retained interim restoration	Overdenture was converted into a screw-retained interim restoration
Second interim restorations	Screw-retained interim restoration with correction of tooth visibility at rest, smile line, lack of parallelism between intercommissural and interpupillary lines with occlusal plane, and tooth proportions.	
Definitive implant-supported rehabilitations	Screw-cementable milled zirconia (Nacera Pearl Multilayer; Nacera) framework with labial ceramic (Creation Zi-CT Gingival; Creation)	Screw-cementable milled high-resistance polymer (Pekkton ivory; Cendres+Métaux) framework with gingival composite resin (anaxgum Pink Composite; anaxdent) and lithium disilicate cemented crowns (e.max Press LT A-1; Ivoclar Vivadent AG)

The Sheffield test was used during clinical evaluation to evaluate the passivity of the frameworks, and intraoral periapical radiographs were made.⁴⁵ Patient compliance, esthetics, and occlusion were also evaluated (Fig. 10). Six-monthly follow-up appointments were scheduled. Three years after the start of treatment, no complications were observed.

DISCUSSION

This completely-edentulous patient was restored with bimaxillary implant-supported prostheses, as adequate lip support, cleansability, and function of the prostheses were demonstrated during the interim restorations phase^{3-6,9,15} used to design the definitive restorations. Recently introduced metal-free materials and manufacturing methods were used, even though, studies evaluating their clinical performance are limited.¹⁵⁻²⁶ The combination of materials was selected based on their different mechanical properties (Table 2). A PEEK framework has reduced weight and a lower flexural strength and modulus of elasticity than the antagonist zirconia prosthesis, which may lead to fewer mechanical complications. However, the cost of the prostheses was higher than that for metal-ceramic or metal-acrylic resin restorations.

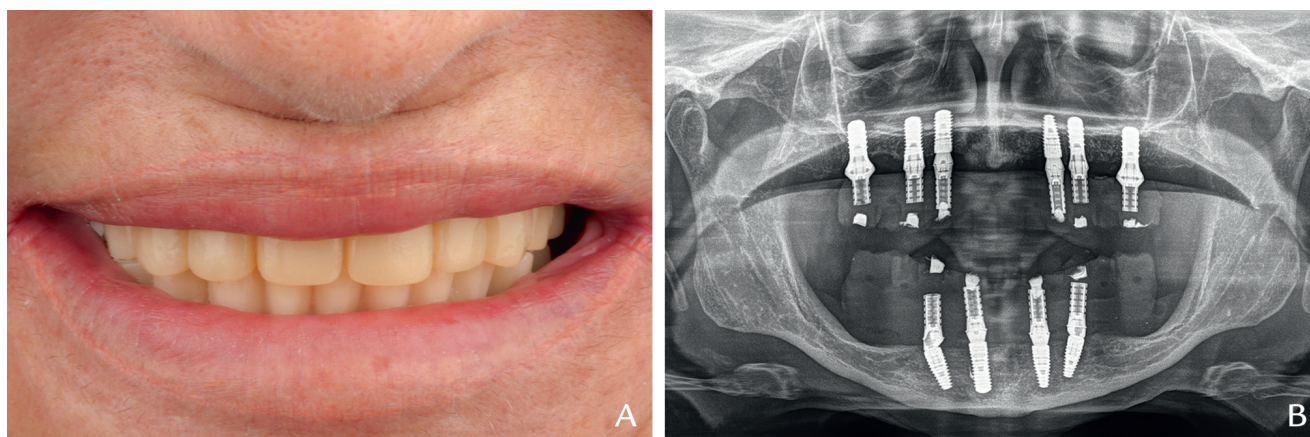


Figure 3. Interim restorations. A, Smile view. B, Panoramic radiograph.

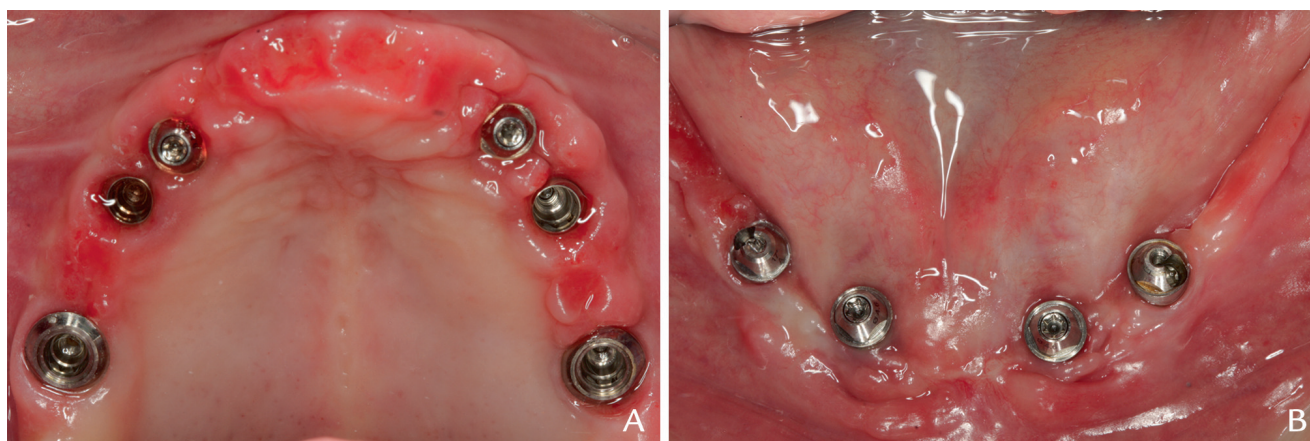


Figure 4. After removal of interim restoration eight weeks after surgery. A, Maxillary occlusal view. B, Mandibular occlusal view.

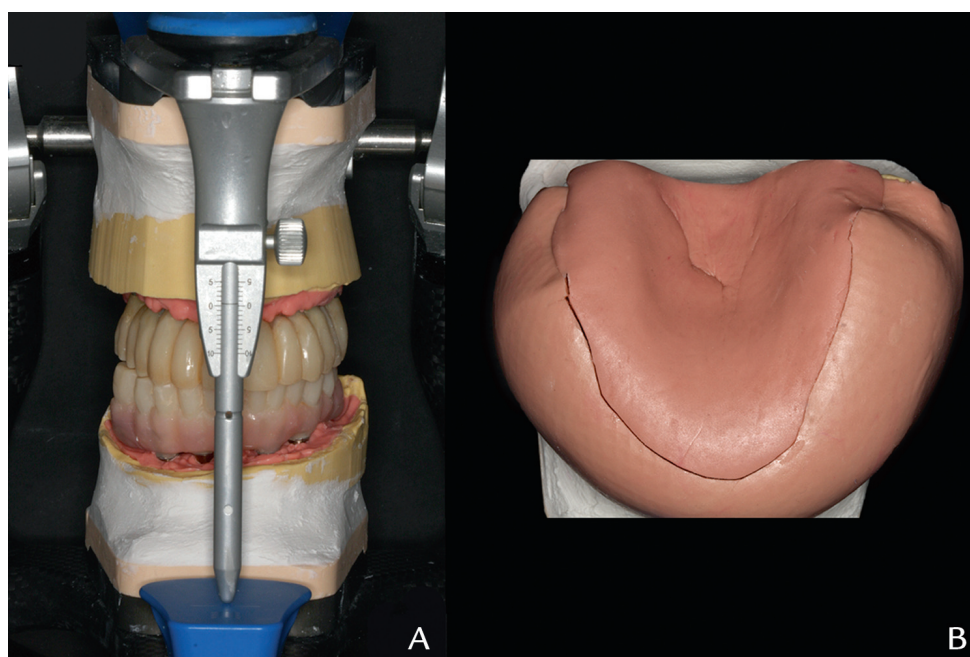


Figure 5. A, Definitive casts mounted in semi-adjustable articulator. B, Silicone index of interim restorations.

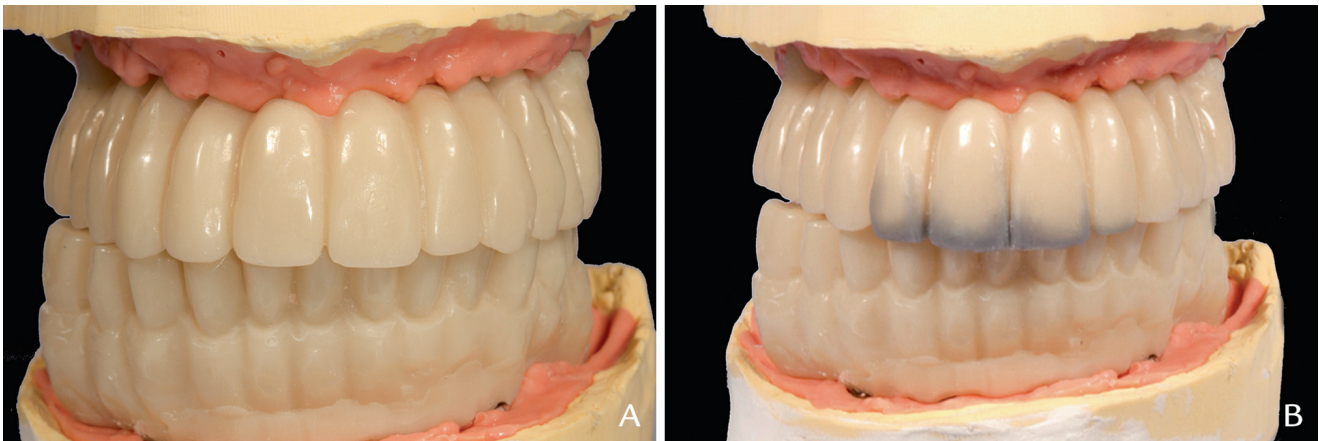


Figure 6. A, Duplicated maxillary and mandibular interim restorations. B, Changes made to occlusal plane.

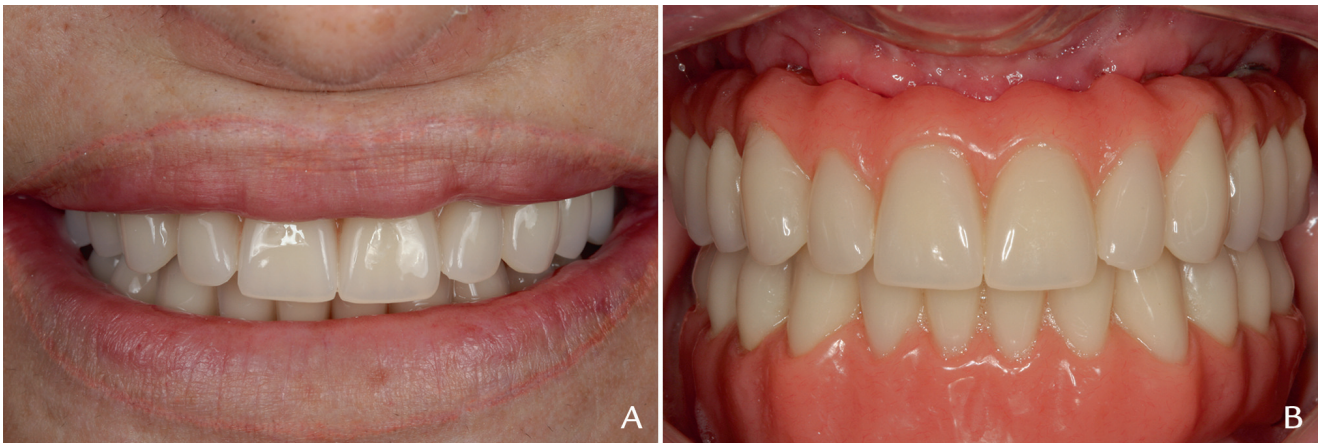

Figure 7. Interim restorations. A, Smile position. B, Frontal view.

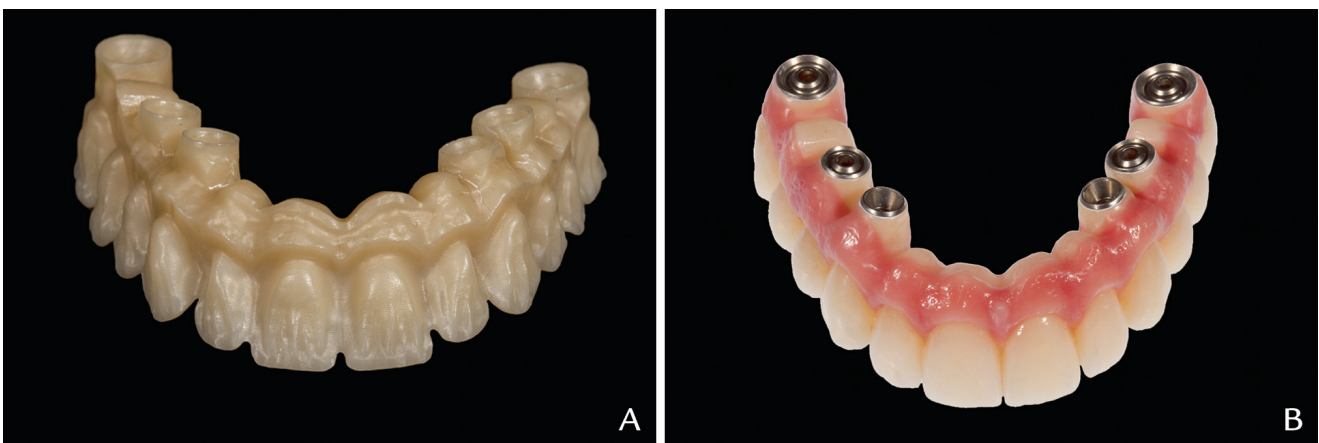


Figure 8. A, Milled monolithic zirconia (Nacera Pearl Multilayer; Nacera) framework with facial cut-back. B, Maxillary implant-supported screw-cementable prosthesis completed, with convex intaglio surface design.

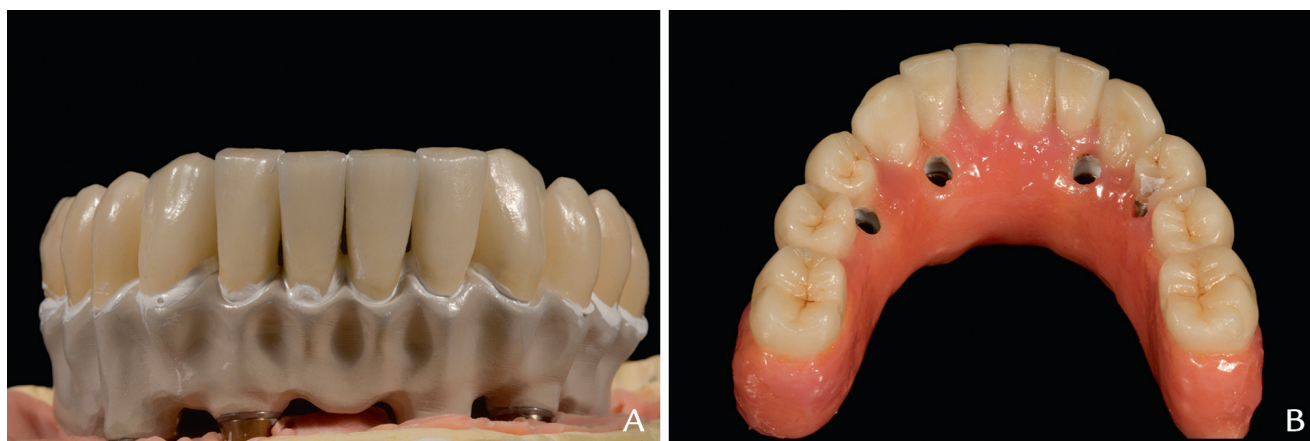


Figure 9. A, Pressed lithium disilicate crowns cemented on milled mandibular PEEK (Pekkton ivory; Cendres Métaux) framework. B, Occlusal view of mandibular implant-supported prosthesis. PEEK, polyetheretherketone.

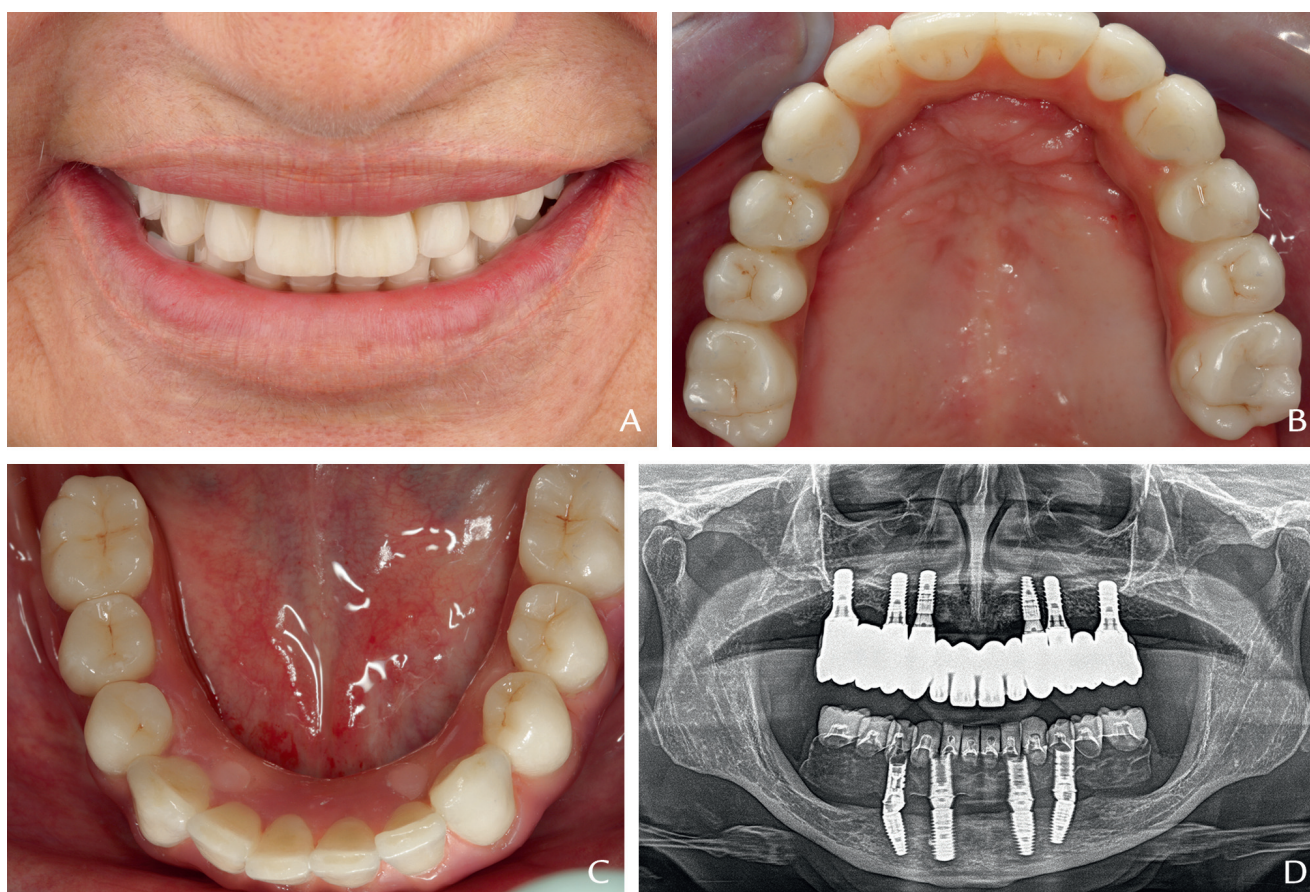

Figure 10. Definitive restorations. A, Smile view. B, Maxillary occlusal view. C, Mandibular occlusal view. D, Panoramic radiograph.

The PEEK material has disadvantages, including an increased minimum connector size, greyish color, and the skill needed for the lithium disilicate crowns.

Monolithic zirconia implant-supported restorations have been reported to be a promising alternative to conventional metal-ceramic designs⁷⁻¹²; however,

chipping of the veneering ceramic has been reported.²⁰ In the present zirconia framework design, only a facial veneer was used to maintain the occlusal contacts in monolithic zirconia material, which may prevent this complication. Clinical studies are needed to evaluate the behavior of these novel materials.

Table 2. Mechanical properties of milled monolithic zirconia material (Nacera Pearl Multilayer; Nacera), high-resistance PEEK polymer (Pekkton ivory; Cendres Métaux), and lithium disilicate ceramic (e.max.Press; Ivoclar Vivadent) selected to fabricate cemented crowns over mandibular framework (manufacturer's data)

Material	3Y-TZP	High-Resistance PEEK Polymer	Lithium Disilicate Ceramic
Commercial name and manufacturer	Nacera Pearl Multilayer; Nacera	Pekkton ivory; Cendres Métaux	e.max Press; Ivoclar Vivadent AG
Composition	ZrO ₂ +HfO ₂ +Y ₂ O ₃ >99% Y ₂ O ₃ 4%-6%	PEEK, titanium oxide	SiO ₂ (57%-80%), Li ₂ O (11%-19%), K ₂ O, P ₂ O ₅ , ZrO ₂ , ZnO, other oxides
Density	>6.04 g/cm ³	NP	2.5 g/cm ³
Flexural strength	1200 MPa	200 MPa	470 MPa
Compressive strength	3000 MPa	NP	
Modulus of elasticity	205 GPa	5.0 GPa	95 GPa
Vickers hardness	1300 HV 0.5	252 MPa	5800 MPa

NP, not provided.

SUMMARY

This clinical report describes restoration of a completely edentulous patient with a rigid monolithic zirconia fixed prosthesis in the maxillary arch and a resilient PEEK prosthesis with lithium disilicate crowns in the mandibular arch. Clinical trials are needed to evaluate the performance of this combination.

REFERENCES

- Jemt T. Failures and complications of 391 consecutively inserted fixed prosthesis supported by Brånemark implants in edentulous jaws: A study of treatment from the time of placement to first annual check-up. *Int J Oral Maxillofac Implants* 1991;6:270-6.
- Zitmann UN, Marinello CP. Treatment plan for restoring the edentulous maxilla with implant-supported restorations: Removable overdenture versus fixed partial denture design. *J Prosthet Dent* 1999;82:188-96.
- Jemt T. Fixed implant supported prosthesis in edentulous maxilla: a five year follow-up report. *Clin Oral Implant Res* 1994;5:142-7.
- Heydecke G, Boudrias P, Awad MA, Albuquerque RF, Lund JP, Feine JS. Within-subject comparisons of maxillary fixed and removable implant prostheses. Patient satisfaction and choice of prosthesis. *Clin Oral Implants Res* 2003;14:125-30.
- Bryant SR, Jankowski D, Kim K. Does the type of implant prostheses affect outcomes for the completely edentulous arch? *Int J Oral Maxillofac Implants* 2007;22:117-39.
- Weber HP, Sukotjo C. Does the type of implant prostheses affect outcomes in the partially edentulous patient? *Int J Oral Maxillofac Implants* 2007;22:140-72.
- Salenbauch MN, Langner J. New ways of designing suprastructures for fixed-implant supported prostheses. *Int J Periodontics Restorative Dent* 1998;18:604-12.
- Heydecke G, Zwahlen M, Nicol A, Nisand D, Payer M, Renouard F, et al. What is the optimal number of implants for fixed reconstructions: a systematic review. *Clin Oral Implants Res* 2012;23:217-28.
- Jemt T, Johansson J. Implant treatment in the edentulous maxillae: a 15-year follow-up study on 76 consecutive patients provided with fixed prostheses. *Clin Implant Dent Relat* 2006;8:61-9.
- Jemt T, Lie A. Accuracy of implant-supported prostheses in the edentulous jaw. *Clin Oral Implants Res* 1995;6:172-80.
- Jemt T, Rubenstein JE, Carlsson L, Lang BR. Measuring fit at the implant prosthodontic interface. *J Prosthet Dent* 1996;75:314-25.
- Harder S, Kern M. Survival and complications of computer aided-designing and computer aided-manufacturing vs. conventionally fabricated implant-supported reconstruction: a systematic review. *Clin Oral Impl Res* 2009;20:48-54.
- Fehmer V, Muhlemann S, Hammerle CH, Sailer I. Criteria for the selection of restoration materials. *Quintessence Int* 2014;45:723-30.
- Wittneben JG, Millen C, Brägger U. Clinical performance of screw- versus cement-retained fixed implant-supported reconstructions - a systematic review. *Int J Oral Maxillofac Implants* 2014;29:84-98.
- Papaspyridakos P, Chen CJ, Chuang SK, Weber HP, Gallucci GO. A systematic review of biologic and technical complications with fixed implant rehabilitations for edentulous patients. *Int J Oral Maxillofac Implants* 2012;27:102-10.
- Venezia P, Torsello F, Cavalcanti R, D'Amato S. Retrospective analysis of 26 complete-arch implant-supported monolithic zirconia prostheses with field-sphatic veneering limited to the facial surface. *J Prosthet Dent* 2015;114:506-12.
- Carames J, Tovar Suinaga L, Yu YC, Pérez A, Kang M. Clinical advantages and limitations of monolithic zirconia restorations full arch implant supported reconstruction: Case series. *Int J Dent* 2015;2015:392496.
- Larsson C, Vult von Steyern P. Ten-year follow-up of implant- supported all-ceramic fixed dental prostheses: A randomized, prospective clinical trial. *Int J Prosthodont* 2016;29:31-4.
- Nishihara H, Haro Adanez M, Att W. Current status of zirconia implants in dentistry: preclinical tests. *J Prosthodont Res* 2019;63:1-14.
- Sailer I, Strassling M, Valente NA, Zwahlen M, Liu S, Pjetursson BE. A systematic review of the survival and complication rates of zirconia-ceramic and metal-ceramic multiple-unit fixed dental prostheses. *Clin Oral Implants Res* 2018;29:184-98.
- Elmougy A, Schiemann AM, Wood D, Pollington S, Martin N. Characterisation of machinable structural polymers in restorative dentistry. *Dent Mater* 2018;34:1509-17.
- Lee KS, Shin SW, Lee SP, Kim JE, Kim JH, Lee JY. Framework prosthesis: A three-dimensional finite element analysis based on cone beam computed tomography and computer-aided design. *Int J Prosthodont* 2017;30:581-5.
- Zoidis P, Papathanasiou I. Modified PEEK resin-bonded fixed dental prosthesis as an interim restoration after implant placement. *J Prosthet Dent* 2016;116:637-41.
- Han KH, Lee JY, Shin SW. Implant- and tooth-supported fixed prostheses using a high-performance polymer (Pekkton) framework. *Int J Prosthodont* 2016;29:451-4.
- Dawson JH, Hyde B, Hurst M, Harris BT, Lin WS. Polyetherketoneketone (PEKK), a framework material for complete fixed and removable dental prostheses: A clinical report. *J Prosthet Dent* 2018;119:867-72.
- Wachtel A, Zimmermann T, Sütel M, Adali U, Abou-Emara M, Müller WD, et al. Bacterial leakage and bending moments of screw-retained, composite-veneered PEEK implant crowns. *J Mech Behav Biomed Mater* 2019;91:32-7.
- Raigrodski AJ, Hillstead MB, Meng GK, Chung KH. Survival and complications of zirconia-based fixed dental prostheses: a systematic review. *J Prosthet Dent* 2012;107:170-7.
- Kim MJ, Oh SH, Kim JH, Ju SW, Seo DG, Jun SH, et al. Wear evaluation of the human enamel opposing different Y-TZP dental ceramics and other porcelains. *J Dent* 2012;40:979-88.
- Stober T, Bermejo JL, Rammelsberg P, Schmitter M. Enamel wear caused by monolithic zirconia crowns after 6 months of clinical use. *J Oral Rehabil* 2014;41:314-22.
- Karl M, Graef F, Wichmann M, Krafft T. Passivity of fit of CAD/CAM and copy-milled frameworks, veneered frameworks, and anatomically contoured, zirconia ceramic, implant-supported fixed prostheses. *J Prosthet Dent* 2012;107:232-8.
- Aparicio C. A new method to routinely achieve passive fit of ceramometal prostheses over Brånemark osseointegrated implants: A two year report. *Int J Periodont Rest Dent* 1994;14:405-19.
- Kaleli N, Sarac D, Külünk S, Öztürk Ö. Effect of different restorative crown and customized abutment materials on stress distribution in single implants

- and peripheral bone: a three-dimensional finite element analysis study. *J Prosthet Dent* 2018;119:437-45.
33. Hahnel S, Wieser A, Lang R, Rosentritt M. Biofilm formation on the surface of modern implant abutment materials. *Clin Oral Implants Res* 2015;26: 1297-301.
 34. Johansson P, Barkarmo S, Hawthorn M, Peruzzi N, Kjellin P, Wennerberg A. Biomechanical, histological, and computed X-ray tomographic analyses of hydroxyapatite coated PEEK implants in an extended healing model in rabbit. *J Biomed Mater Res A* 2018;106:1440-7.
 35. Kern M, Lehmann F. Influence of surface conditioning on bonding to poly-etheretherketon (PEEK). *Dent Mater* 2012;28:1280-3.
 36. Stawarczyk B, Taufall S, Roos M, Schmidlin PR, Lümekemann N. Bonding of composite resins to PEEK: the influence of adhesive systems and air-abrasion parameters. *Clin Oral Investig* 2018;22:763-71.
 37. Yuodelis RA, Faucher R. Provisional restorations: an integrated approach to periodontics and restorative dentistry. *Dent Clin North Am* 1980;24: 285-303.
 38. Gallucci GO, Bernard JP, Bertosa M, Belser UC. Immediate loading with fixed screw-retained provisional restorations in edentulous jaws: The pickup technique. *Int J Oral Maxillofac Impl* 2004;19:524-33.
 39. Rodríguez X, Vela X, Méndez V, Segalà M, Calvo-Guirado JL, Tarnow DP. The effect of abutment dis/reconnections on peri-implant bone resorption: a radiologic study of platform-switched and non-platform-switched implants placed in animals. *Clin Oral Implants Res* 2013;24:305-11.
 40. Nóvoa L, Batalla P, Caneiro L, Pico A, Liñares A, Blanco J. Influence of abutment height on maintenance of peri-implant crestal bone at bone-level implants: A 3-year follow-up study. *Int J Periodontics Restorative Dent* 2017;37:721-7.
 41. Blanco J, Pico A, Caneiro L, Nóvoa L, Batalla P, Martín-Lancharro P. Effect of abutment height on interproximal implant bone level in the early healing: A randomized clinical trial. *Clin Oral Implants Res* 2018;29:108-17.
 42. Martin WC, Pollini A, Morton D. The influence of restorative procedures on esthetic outcomes in implant dentistry: a systematic review. *Int J Oral Maxillofac Implants* 2014;29:142-54.
 43. Baig MR. Accuracy of impressions of multiple implants in the edentulous arch: a systematic review. *Int J Oral Maxillofac Implants* 2014;29:869-80.
 44. Fradeani M, Barducci G. Esthetic rehabilitation in fixed prosthodontics. In: *Prosthetic treatment: A systematic approach to esthetic, biologic, and functional integration*. Vol 2. 1st ed. Chicago: Quintessence Pub Co; 2008. p. 30-45.
 45. Jemt T. Three-dimensional distortion of gold alloy casting and welded titanium frameworks. Measurements of the precision of fit between completed implant prostheses and the master cast in routine edentulous situations. *J Oral Rehabil* 1995;22:557-64.

Corresponding author:

Dr Marta Revilla-León
Comprehensive Dentistry Department
College of Dentistry
Texas A&M University
3302 Gaston Avenue
Room 713
Dallas, TX 75246
Email: revillaleon@tamu.edu

Copyright © 2019 by the Editorial Council for *The Journal of Prosthetic Dentistry*.
<https://doi.org/10.1016/j.prosdent.2019.10.002>